

Breast Imaging with a Positron Edge

Advances in positron emission mammography


By Kathy Schilling, MD

In women with newly diagnosed breast cancer, mammography and clinical breast examination often do not depict the full extent of cancer. While MRI has been shown to be highly sensitive in detecting tumors, many non-cancerous lesions also appear suspicious. Positron emission mammography is another way to image breast cancer, using a high-resolution PET scanner to image areas where there is increased metabolism of glucose.

IN NEWLY DIAGNOSED BREAST CANCER PATIENTS WHO ARE THOUGHT TO BE CANDIDATES FOR LUMPECTOMY SURGERY,

mammography and clinical breast examination often do not depict the full extent of cancer. While MRI has been shown to be highly sensitive in depicting the full extent of tumor, many non-cancerous lesions also appear suspicious. Recently, there has been a push toward a new alternative, which has been shown in studies to be as effective, if not more so, than MRI.

Positron emission mammography (PEM) is a high-resolution imaging technique performed with a dedicated breast PET scanner. In 1993, Christopher J. Thompson, DSc, introduced PEM technology



Kathy Schilling, MD

with two flat detectors, which were positioned on either side of a compressed breast. He found high-count efficiency due to the proximity of the detectors to the target organ and small volume of attenuating distance between the detectors. This resulted in improved spatial resolution compared to whole-body PET (WBPET) using iterative limited angle reconstruction techniques. Initial imaging was performed with the device mounted on a stereotactic table, which permitted good X-ray correlation

of findings, but had the limitation of poor visualization of posterior breast tissue.

The second-generation scanner was a freestanding device, which resembles a small mammography unit on wheels and a computer acquisition station. The two detectors are made of 2000 lutetium-containing photo detection crystals, which are mounted in the compression paddles. During image acquisition, the detectors move within the paddles, acquiring coincident counts. The user has the ability to select the travel distance of the detectors to customize the breast coverage. This becomes important as PEM biopsy is performed.

Three-dimensional data is collected and an iterative reconstruction provides a composite image, as well as 12 tomographic images with each slice having the thickness corresponding to the compression distance divided by 12. At a review workstation, distance measurements, region-of-interest (ROI), standardized uptake values (SUV) analysis, and variable image display capabilities exist.

THE PRINCIPLES OF PEM IMAGING

Cancer cells have certain biological features, such as abnormal glucose metabolism, abnormal cell proliferation, hypoxia, and abnormal cell perfusion. This abnormal metabolic activity is used to evaluate the accumulation of F-18 bound to fluorodeoxyglucose (FDG) within the cells.

This glucose analog is trapped within the cells and not metabolized, causing accumulation of the radioisotope within the cell. PEM is designed to visualize and measure this accumulation. The F-18 in FDG decays by positron emission with a half-life of 110 minutes. During this process, there is an annihilation of the positron by an electron, creating two 511 keV gamma rays emitted in opposite directions, which are then detected by photon detectors.

PET and PEM use similar imaging principles; however, the camera used for PEM has been optimized to be able to detect especially small breast cancers.

THE TECHNIQUE

Patients are instructed to fast four hours prior to the exam, and a fasting blood sugar is obtained. The exam is performed on those patients with a fasting glucose of <140mg/dl. A high-protein, low-carbohydrate diet prior to the exam can be recommended to those with difficult-to-control sugars. The patient is injected with 10-12mCi of F-18 FDG and rests quietly for one hour prior to imaging. During this period, quality control measures are performed on the acquisition station to ensure reproducibility of SUV using a sealed positron emitter source.

Prior to imaging, the patient is instructed to void. Initially, a short scan of the injection site will identify infiltration of the dose in tissues. In a seated position, two views of each breast are obtained at a minimum, including the craniocaudad and mediolateral oblique. These are best obtained utilizing mammography technologists, to maximize tissue placed within the field of view of the camera. Individual images are obtained with immobilization of the breast, using the 24cm by 17cm compression plates with 10-minute acquisition acquiring 1 million coincident counts. Additional views to include lateral, cleavage, and axillary imaging can be added as needed, and imaging time can be reduced once standard views are obtained.

The interpretation of the exam is performed after review of patient history and concurrent imaging studies. Initially, identification of FDG uptake within the background breast tissue is performed.

An increased background glandular tissue results in increasing SUV. Study director, Wendie Berg, MD, PhD, reported an average SUVmean of fatty tissue of 0.33, scattered fibroglandular tissue of 0.41, heterogeneously dense tissue of 0.65, and dense tissue of 0.85.

The background SUV should be obtained in the region of greatest breast density. Images are then evaluated for symmetry in uptake and identification of hot spots. Once identified, the size, location, and SUVmax of the lesion is obtained. The PEM Uptake Value (PUV) is the lesion SUVmax to background SUVmean ratio. This value has been the best predictor of malignancy, rather than a strict threshold. Berg, who is also a diagnostic radiologist specializing in breast imaging at American Radiology Services-Johns Hopkins Greenspring in Lutherville, Md., reported that, if a threshold had been used to identify 45 breast cancers, more than half would have been misclassified as benign.

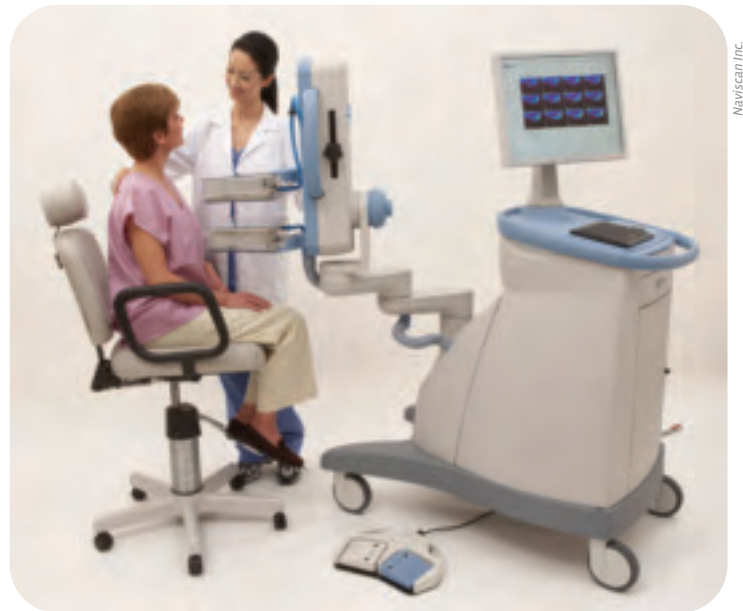The PUV has been found to correlate with the severity of lesion pathology. According to Berg, atypical ductal hyperplasia (ADH) had an average PUV of 1.45; ductal carcinoma in situ (DCIS), PUV of 2.08; pure invasive ductal carcinoma (IDC), PUV of 2.83; and invasive lobular carcinoma (ILC), PUV of 1.49. This becomes important as we consider PEM for the evaluation of our high-risk patients where MRI is limited by specificity. PEM has the ability to detect ADH and can be used as a monitoring tool. Once detected, medical and surgical prophylaxis can then be offered.

Reporting of the exam includes size of lesion and location, as well as morphologic breast imaging reporting and data system (BIRADS) descriptors and PUV. The presence or absence of axillary disease should also be commented on. Artifacts, high background uptake of FDG, poor patient positioning, and inflammation may limit evaluation and should be commented on as a disclaimer. If unsuspected lesions are found, targeted ultrasound has been successful in lesion localization and characterization. If identified, ultrasound biopsy can then be performed.

THE OUTCOMES WITH PEM

Results of the first PEM pilot study in breast cancer were performed on a first-generation scanner with 10mm crystal by Lorraine Tafra, MD, director of Anne Arundel Medical Center's Breast Center in Annapolis, Md. Of the 44 women with known breast cancer, 39 were detected with PEM. Additionally, of the 19 patients undergoing breast conservation surgery, PEM correctly predicted 75 percent of patients with positive margins and 100 percent of patients with negative margins. PEM also detected four of five incidental breast cancers, three of which were not seen by any other imaging modality. The authors concluded that PEM was valuable in breast cancer detection and surgical planning of breast conservation therapy.

In 2006, Berg conducted a multi-center trial that examined the performance of PEM in women with known breast cancer or suspicious imaging findings. PEM was found to have a cancer detection sensitivity of 91 percent, specificity of 93 percent, negative predictive value of 88 percent, and accuracy of 92 percent. Of note was that PEM was able to identify 91 percent of DCIS preoperatively. In this study, 36 of 73 biopsies (49 percent) generated by conventional imaging alone proved to be benign, with a positive predictive value of 95 percent. This suggests the combination of anatomic and metabolic characterization of lesions improves performance.



Naviscan Inc

PEM imaging is obtained in a manner similar to mammography. The PEM detectors are mounted on the two compression paddles, with 1000 lutetium photodetecting crystals present on each detector. PEM image acquisition is approximately 10 minutes, with 1 million coincident counts obtained for image production. Spatial resolution is 1.5mm, the highest resolution of any biochemical breast imaging modality, permitting the imaging of breast ductal structures.

I presented initial findings of 39 cancers found in 28 patients evaluated with WBPET, PEM, and MRI in 2007. PEM was found to have the greatest sensitivity of 92.3 percent, while WBPET was found to have a sensitivity of only 39 percent. The sensitivity of MRI was similar to PEM. Additionally reported was the fact that PEM did not appear to be adversely affected by hormonal changes, which occur during the menstrual cycle, unlike breast MRI.

In an attempt to improve detection sensitivity and specificity, Lee P. Adler, MD, from the Department of Nuclear Medicine at Philadelphia-based Fox Chase Cancer Center, investigated the application of dual-time point imaging with PEM in a small study with 11 patients. He found a median increase in the lesion-to-background ratio of 36 percent, with a range from 16 percent to 85 percent. This appears to occur as there is a reduction in background level of FDG with time. Adler also noted that 100 percent of three benign lesions showed a decrease in the lesion-to-background ratio, suggesting that delayed imaging may assist in discriminating benign from malignant lesions.

At RSNA in 2008, I presented results from my first 250 women with recent diagnosis of breast cancer who were imaged with WBPET, PEM, and MRI for presurgical staging, in which 208 patients were evaluable. I found that PEM successfully identified 93 percent of DCIS compared to MRI, which had a sensitivity of only 79 percent. The sensitivity for identification of invasive cancers was similar, at 93 percent. Of particular importance is the finding that PEM identified half the number of false positives as MRI, which resulted in a specificity for PEM of 73 percent compared to 43 percent for MRI. This finding was consistent despite menopausal status or breast density. With this in mind, perhaps PEM will be better suited for high-risk screening of our BRCA patients, resulting in fewer unnecessary biopsies and accurately identifying breast cancer at its earliest presentation. In 2008, the FDA approved a PEM-guided biopsy using a vacuum-assisted device.



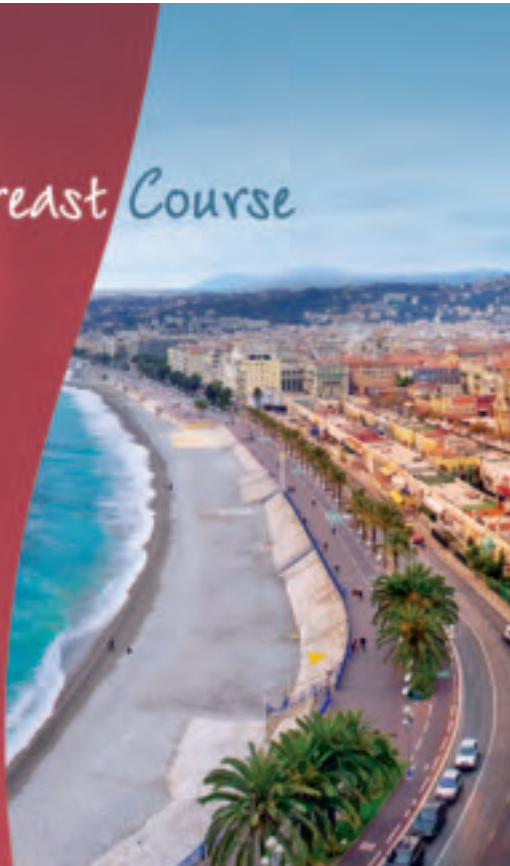The Breast Course 2009

**BREAST DISEASES:
DETECTION, INTERVENTION
AND THERAPY**

RADISSON SAS, NICE, FRANCE

APRIL 26-29 2009

www.thebreastpractices.com



LOOKING FORWARD

While mammography continues to be the gold standard technique for breast cancer screening, other techniques are providing information beyond the morphologic status of the tumor and are giving fascinating information about the molecular aspects of breast cancers. The current trends of imaging and therapy are tailored to each individual. More and more, we see the use of uniquely designed personalized therapies using biological and biomolecular features of the tumor, as well as molecular predictive markers. Breast imaging using new positron-emitting agents, such as cell proliferation markers and estradiol analogs, provide an approach to monitor and predict clinical response to targeted and hormonal therapies. PEM is a promising technique; however, more research is needed with larger population groups.

Until prevention and universal cures are discovered for breast cancer, the only opportunity women have to reduce the chance of dying from breast cancer is through screening imaging studies.

Kathy Schilling, MD, is the medical director of imaging and intervention at the Center for Breast Care at Boca Raton Community Hospital in Florida. Questions and comments can be directed to editorial@rt-image.com.

Make AAMD 2009 Meetings Your Source for Continuing Education!



Educational Sessions

More than 60 CE credits available for medical dosimetrists, medical physicists and radiation therapists

Networking

Discuss issues and ideas with colleagues

Exhibits

See the latest radiation oncology products and technologies

For complete details on these 3 AAMD meetings, visit www.medicaldosimetry.org

AAMD Region I and AAPM Northwest Chapter Spring Meeting

March 20-21, 2009
Skamania Lodge
Stevenson, WA

2009 AAMD Region V Meeting Catch the Wave

April 3-4, 2009
Beach Cove Resort
North Myrtle Beach, SC

AAMD 34th Annual Meeting

June 21-25, 2009
Fairmont Scottsdale
Scottsdale, AZ

